

## RESEARCH ARTICLE

# RADIOLOGIC INDICES OF CARDIAC MENSURATION IN THE AFRICAN GRASSCUTTER (*THRIONOMYS SWINDERIANUS*)

Chikera Samuel Ibe<sup>1</sup>, Rock Odinma Ukaha<sup>2\*</sup>, Njoku Uchechukwu Njoku<sup>2</sup>, Kelechi Theresah Jeremiah<sup>2</sup>, Celestine Okwudili Ukwueze<sup>2</sup>, Eugenie Yongo Tchokote<sup>3</sup>, Chidi Johakim Okonkwo<sup>3</sup>, Chioma Unamba-Oparah<sup>3</sup>

<sup>1</sup>Departments of Veterinary Anatomy, College of Veterinary Medicine, Michael Okpara University of Agriculture, Umudike, Abia State, Nigeria

<sup>2</sup>Departments of Veterinary Surgery and Radiology, College of Veterinary Medicine, Michael Okpara University of Agriculture, Umudike, Abia State, Nigeria

<sup>3</sup>Veterinary Medicine, College of Veterinary Medicine, Michael Okpara University of Agriculture, Umudike, Abia State, Nigeria

**\*Corresponding author:**

Dr. Rock Odinma Ukaha

**Address:** College of Veterinary Medicine, Michael Okpara University of Agriculture, Umudike 440101, Abia, Nigeria

**Phone:** +2348061530565

**ORCID:** 0000-0001-7678-4241

**E-mail:** ukaha.rock@mouau.edu.ng

**How to cite this article:** Ibe CS, Ukaha RO, Njoku UNJ, Jeremiah KT, Ukwueze CO, Tchokote EY, Okonkwo CJ, Unamba-Oparah C. 2024. Radiologic indices of cardiac mensuration in the African Grasscutter (*Thryonomys Swinderianus*). Veterinaria, 73(1), 13-24.

## ABSTRACT

This research aimed to establish reference radiographic indices for future cardio-thoracic appraisals in the African grasscutter. Twenty healthy animals consisting of equal number of juveniles and adults were used. Forty thoracic projections consisting of dorsoventral (DV), ventrodorsal (VD), right lateral (RtL) and left lateral (LeL) views were acquired. The evaluated parameters included thoracic and cardiac diameters on the DV/VD radiographs, and cardiac long and short axes on the RtL/LeL radiographs. Cardiac indices generated were cardio-thoracic ratio (CTR), vertebral heart score (VHS) and cardiac axis ratio (CAR). The reference values of CTR on VD and DV were  $0.52 \pm 0.02$  and  $0.50 \pm 0.02$ , respectively. The difference was not significant ( $P > 0.05$ ). The mean radiographic values of CTR for juvenile and adults on DV were  $0.48 \pm 0.04$  and  $0.52 \pm 0.01$ , respectively. The reference values of VHS on RtL and LeL were  $8.70 \pm 0.23$  and  $8.60 \pm 0.21$ , respectively. The difference was not significant ( $P > 0.05$ ). The mean values of VHS for juveniles and adults on RtL were  $8.20 \pm 0.30$  and  $9.20 \pm 0.12$ , respectively. The difference was not significant ( $P > 0.05$ ). These indices are relevant in future diagnosis of cardiac diseases in the African grasscutter.

**Keywords:** African grasscutter, cardiac axis ratio, cardio-thoracic ratio, radiology, vertebral heart score

## INTRODUCTION

In veterinary diagnostic radiology, thoracic projections are usually obtained and evaluated for patients presenting cardio-thoracic manifestations. In such investigations, the heart size and other thoracic organ dimensions are determined. Previously, clinicians read thoracic radiographs based on subjective or personal opinion of structures assessed, oftentimes resulting in high error margin. The advent of measurement methods in radio-diagnostics has proved more sensitive and accurate, eliminating the high error margin associated with subjective interpretation (Ukaha et al., 2002; Hansson, 2004). These radiographic measurements generate indices that depict the size of the cardiac silhouette. These indices are usually achieved by measurements made on four key thoracic radiographic projections, namely, dorsoventral (DV), ventrodorsal (VD), right lateral (RtL), and left lateral (LeL) projections. Dennis et al. (2010) opined that increased diagnostic yield and accuracy of cardio-thoracic radiographic appraisals is achieved by the use of these four thoracic radiographic projections. Some of the radiographic indices that depict the size of cardiac silhouette include the cardio-clavicular ratio (Gardner et al., 2007), cardiac long axis-thoracic height ratio (Diniz et al., 2013), vertebral heart score (VHS) (Luciani et al., 2019), vertebral left atrial size (Puccinelli et al., 2021), cardio-thoracic ratio (CTR) (Sak and Pazvant, 2021), aortico-cardiac ratio (Ukaha et al., 2002) and cardiac axis ratio (CAR) (Ukaha et al., 2002). However, CTR, VHS and CAR are of interest in the present study.

The CTR is the ratio of the maximum diameter of the cardiac silhouette to the thoracic diameter, obtained on a VD or DV radiographic projection. It is used to determine the difference between normal and enlarged cardiac silhouette. Therefore, it is beneficial in diagnosis of heart diseases (Baisan et al., 2016). The study of Hemingway et al. (1998) showed striking evidence that CTR of healthy animals, within the range considered normal in clinical practice, can predict coronary heart disease mortality, independent of established

coronary heart disease risk factors such as blood pressure. It provides an accurate measure of the left ventricular mass, which can be extrapolated to myocardial ischaemia or infarction and pericardial effusion (Baisan et al., 2016). Monitoring CTR of any animal diagnosed of cardiovascular disease is very important to the clinician, as it helps in predicting the severity and progress of the condition (Oguntoyinbo et al., 2016).

The VHS is an easy and objective radiographic method routinely employed to establish normal heart size (Buchanan, 2000; Sleeper and Buchanan, 2001) and monitor changes in heart size due to therapy or cardio-thoracic disease (Sleeper and Buchanan, 2001). It usually serves as a reference in the diagnosis of cardiomegaly (Luciani et al., 2019). It is the summation of the number of thoracic vertebral bodies scaled by the radiographic values of the short and long cardiac axes. It is obtained by placing the vernier caliper of a defined cardiac axis over the thoracic vertebrae, parallel to the vertebral canal, and counting caudally, from the cranial extremity of the body of the 4th thoracic vertebrae, to the nearest 0.1-0.5 vertebra. Unlike the CTR that can be obtained on either the VD or DV projections only, VHS can be obtained from any of the four key thoracic radiographic projections (Luciani et al., 2019; Dias et al., 2021). A strong positive correlation has been recorded between CTR and VHS in capuchin monkeys (Rocha-Neto et al., 2015) and dogs (Baisan et al., 2016). This suggests that both indices are valid methods that can be used in the discrimination between normal heart size and cardiomegaly or microcardia in these species. The CAR, an index that measures the ratio of the short axis to the long axis of the heart on a lateral view, has been established for the male and female as well as for puppy and adult Nigerian indigenous dog (Ukaha et al., 2002). It is not influenced by respiratory phases, unlike CTR, thus, must not be taken at full inspiration (Ukaha et al., 2002).

Thoracic radiography is a less expensive, less technical, and widely acceptable imaging modality for the non-invasive evaluation of thoracic organs and diagnosis of cardio-pathologies in veterinary clinical practice, when compared with a more

advanced procedure such as echocardiography. It has been widely applied in dogs, with information available for various local and exotic breeds. Unfortunately, those results have limitations and cannot be applied to other breeds of dogs or species of animals, because of conformational differences in body shapes of animals (Gulanber et al., 2005). Therefore, reference radiographic values ought to be established and published specifically for every animal. Over the years, thoracic radiography has been used to establish normal heart size and diagnose cardiac anomalies in rodents such as African hedgehogs (Black et al., 2011), agouti (Diniz et al., 2013; De Moura et al., 2015), laboratory mice (Ulum and Noviana, 2018), pet rats (Dias et al., 2021) and guinea pigs (De Silva et al., 2022). However, to the best of the authors' knowledge, this is the first time this diagnostic image modality is applied to establish cardiac indices in the African grasscutter (*Thryonomys swinderianus*).

Results of this study will serve as normal radiologic reference values of cardiac mensuration in the African grasscutter, necessary for the diagnosis of cardiovascular anomalies in the rodent. This is necessary as this large wild rodent, the fourth largest in the world, is currently bred and domesticated as an integral component of the mini- livestock industry in Nigeria and elsewhere (Ibe et al., 2023). Literature has already documented reports of clinical signs of heart failure which occurred sporadically in captive colonies of African grasscutters derived from in-bred male and female litter mates (Rahman et al., 2015). Consequently, the specific objectives of the present study were to establish and compare reference values of CTR in juvenile and adult African grasscutters from measured CD and TD obtained on VD and DV projections of plain radiographs; establish and compare reference values of VHS and CAR in juvenile and adult African grasscutters from measured SA and LA of the heart obtained on RtL and LeL projections of plain radiographs; compare the established reference values with those of other members of the order Rodentia and class Mammalia in available literature.

## MATERIAL AND METHODS

### Ethical approval

The experimental procedure has the approval of the Research Ethics Committee, College of Veterinary Medicine, Michael Okpara University of Agriculture Umudike, Nigeria. The approval reference number is MOUAU/CVM/REC/202214. Management of the experimental animals was as stipulated in the Guide for the Care and Use of Laboratory Animals, 8<sup>th</sup> Edition, National Research Council, USA (National Academic Press, Washington, DC: <http://www.nap.edu>).

### Experimental animals and management

Twenty African grasscutters (*Thryonomys swinderianus*) of known ages were used for the study. Ten of the animals were purchased as weaners at the age of one month and one week from an organized grasscutter farm in Ibadan, Nigeria. The remaining ten were purchased as adults between the ages of 15 and 17 months, from an organized grasscutter farm in Umuahia, Nigeria. The animals were transported in well ventilated wooden cages to the animal holding of the Radiology Unit in the College of Veterinary Medicine, Michael Okpara University of Agriculture, Umudike, Nigeria. Here, they were transferred into, and kept singly, in standard laboratory cages, specific for housing large rodents like African grasscutters.

The puppies were managed for three months to attain the juvenile age (four months). During this period, the adults were also acclimatized for two weeks. All animals were fed with cane grass, corn cob, husk and entire maize plant, potato, yam and paw-paw peels, foraged legumes such as *Centrosema macrocarpum* and *Calopogonium caeruleum*. These plants were supplemented with concentrates (Chikun Finisher<sup>®</sup>). Drinking water was provided *ad libitum*. They were clinically examined and ascertained to be apparently healthy, based on the absence of prior clinical conditions documented by the grasscutter farm, and the clinical examinations. On a daily basis, the cages were cleaned and the litters were replaced with fresh feed.

## Anesthetic protocol

The animals were restrained physically for weighing, using a well-ventilated metal cage of known weight. The animal's weight was obtained by subtracting the weight of the cage from the combined weights of the animal and the restraint cage. Animals' weights were obtained using a baby scale. Thereafter, the animals were sedated with Xylazine hydrochloride (XYL-M2®, Belgium; 2.0mg/Kg/IM). Five minutes later, they were anaesthetized with ketamine hydrochloride (Jawa Ketamine®, Swiss Parenterals India; 8.0mg/Kg/IM). This was to reduce experimental stress and ensure compliance of the animals as well as safety of the radiologist. Vital signs were monitored using a stethoscope (Classic II Infant 28' Stethoscope, Littmann 3 M, USA) and rectal thermometer (Electro-therm TC100A, Cooper Instruments, Virginia, USA).

## Radiographic exposures

The animals were carefully placed on the radiographic table so that the radiographs were centered and collimated to the thorax (Figure 1). Forelimb-ties and sandbags were employed to achieve maximum collimation. Blue-sensitive radiographic films (BEGOOD® Medical X-ray Films China, 24 x 30 cm; 100NIF), loaded in the dark room, were exposed at full inspiration using a mobile X-ray machine (Dean Dynamax 40; GEC Medical Equipment Group Ltd, England; 44kVp; 10 mAs; 90 cm focus film-distance; 0 cm object film-distance). Only one radiologist performed all exposures in order to reduce exposure bias and variation. The VD (Figure 1), DV, RtL and LeL projections of the thorax were obtained from each animal. Exposed films were routinely processed in a dark room and studied using an X-ray viewer. Images of the radiographs were obtained with a digital camera (Casio Exilim EX-H5, USA; 12.1 Megapixel).



**Figure 1** An adult African grasscutter positioned with forelimb-ties and sandbags for VD radiographic projection of the thorax

## Landmarks for radiographic measurements

The thoracic indices obtained on the VD and DV projections were the CD and TD, from which the CTR was computed for each animal. Furthermore, the LA and SA were thoracic indices obtained on the RtL and LeL projections, for the computation of VHS and CAR for each animal. The indices were measured with a digital vernier caliper (British Whitworth tools, UK; sensitivity: 0.01mm). Landmarks for the measurements include:

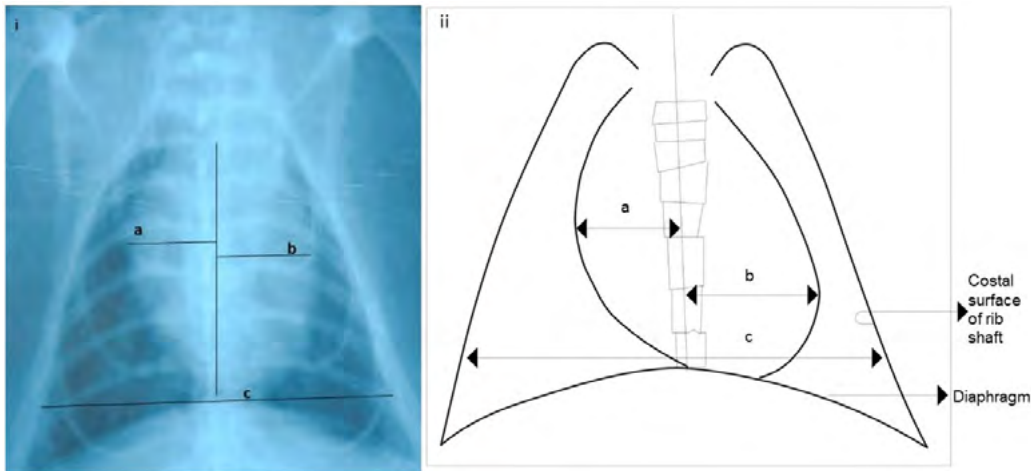
1. Cardiac diameter (CD): summation of two transverse lines (a + b), each measured from the mid-sagittal to the widest lateral margin of the heart (Figure 2).
2. Thoracic diameter (TD): a transverse distance between the costal surfaces of the shafts of two corresponding ribs at the level of the apex of the right diaphragmatic dome (Figure 2: c).
3. Cardio-thoracic ratio (CTR):  
$$\text{CTR} = \frac{\text{CD}}{\text{TD}}$$
4. Short axis (SA): the widest distance, perpendicular to the long axis, between the cranial and caudal borders of the heart (Figure 3: a).



5. Long axis (LA): a distance from the base of the heart, at the level of tracheal bifurcation (carina), to its apex (Figure 3: b)
6. Vertebral heart score (VHS): summation of the number of thoracic vertebral bodies scaled by the radiographic values of SA and LA, obtained by placing the vernier caliper representing

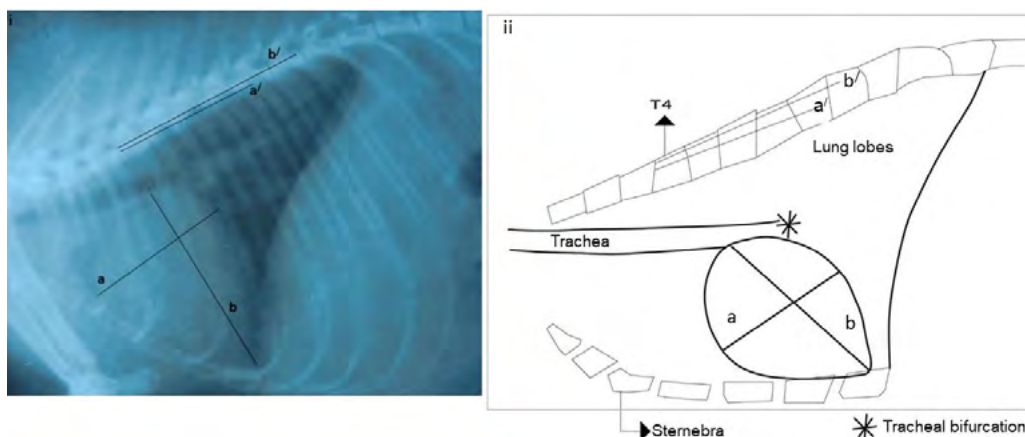
the value of SA and LA over the thoracic vertebrae, parallel to the vertebral canal, and counting caudally, from the cranial extremity of the body of the 4<sup>th</sup> thoracic vertebrae to the nearest 0.5 vertebra (Figure 3: a' + b').

7. Cardiac axis ratio (CAR):  $SA \div LA$



**Figure 2** Landmark for radiographic measurement of CD (a + b) and TD (c) in the African grasscutter

(i) Plain radiograph (VD Projection) of the adult African grasscutter; (ii) Schematic representation of the radiograph



**Figure 3** Landmark for radiographic measurement of SA (a), LA (b) and VHS (number of vertebral body units represented by a' + b') in the African grasscutter

(i) Plain radiograph (LeL Projection) of the juvenile African grasscutter; (ii) Schematic representation of the radiograph

## Statistical analysis

The data obtained were analyzed using a commercially available statistical software for Windows operation system, GraphPad 5.0 (GraphPad Software Inc, San Diego, CA, USA). The mean radiographic values  $\pm$  Standard Error of Mean (SEM) of all the measured indices and ratios from animals in each age group were obtained and represented in tables and graphs. The mean radiographic values of CD, TD, SA and LA were compared between opposite radiographic projections in each of the two age groups using two-tailed t-test. The mean radiographic values of the CTR, VHS and CAR of the juveniles and adults were also compared using the two-tailed t-test. In each of the two age groups, Pearson correlation coefficient was calculated to evaluate the association between each of CTR, VHS and CAR with nose-rump length. Values of  $P \leq 0.05$  were considered statistically significant.

## RESULTS

The mean body weight and nose-rump length of the adult African grasscutters used for this study were  $2.59 \pm 3.37$  kg (95% range: 1.95-3.85 kg) and  $462.7 \pm 16.22$  mm (95% range: 407.6-500.2 mm), respectively. Similarly, the mean body weight and nose-rump length of the juveniles were  $0.78 \pm 0.14$  kg (95% range: 0.23-1.00 kg) and  $260.2 \pm 16.49$  mm (95% range: 200.1-293.9 mm), respectively. Irrespective of the age, each animal presented a cardiac silhouette located between the 3<sup>rd</sup> and 5<sup>th</sup> intercostal space in the middle mediastinum.

Reference values of CTR, VHS and CAR in the African grasscutter

Table 1 shows the reference values of some cardiac mensuration (CTR, VHS and CAR) in the African grasscutter, obtained from opposite radiographic projections, irrespective of age. There was no significant difference in the radiographic values of any of the indices between opposite radiographic projections ( $P > 0.05$ ).

**Table 1** Reference Values of CTR, VHS and CAR in the African grasscutter

	CTR		VHS		CAR	
	VD	DV	RtL	LeL	RtL	LeL
Minimum	0.42	0.39	7.00	7.00	0.67	0.67
Maximum	0.64	0.61	9.50	9.50	0.73	0.81
Mean ( $\pm$ SEM)	$0.52 \pm 0.02^a$	$0.50 \pm 0.02^a$	$8.70 \pm 0.23^b$	$8.60 \pm 0.21^b$	$0.70 \pm 0.01^c$	$0.71 \pm 0.02^c$

<sup>a-c</sup>Mean ( $\pm$  SEM) values of a radiographic thoracic index with the same alphabet superscript are not statistically different between opposite radiographic projections ( $P > 0.05$ )

Comparison of CTR between juvenile and adult African grasscutters

Table 2 shows the mean radiographic values of the CD, TD and CTR obtained on the VD and DV projections, in each of the two age groups. There was no significant difference in the radiographic values of CD between the VD and DV projections in any of the two age groups ( $P > 0.05$ ). Similar findings were made for the TD and CTR. Figure 4 is a chart that compared the mean radiographic values of CTR between juvenile and adult age

groups, obtained on the DV and VD projections. The result did not show any significant difference in mean radiographic values obtained on either the DV or VD projections ( $P > 0.05$ ). There was a significant negative linear correlation between the radiographic values of CTR and nose-rump length in the juveniles ( $R^2 = 0.91$ ;  $P < 0.05$ ). A regression formula was deduced from the graph (Figure 5), as  $y = -0.0021x + 1.0297$ ;  $y$  being the CTR (dependent

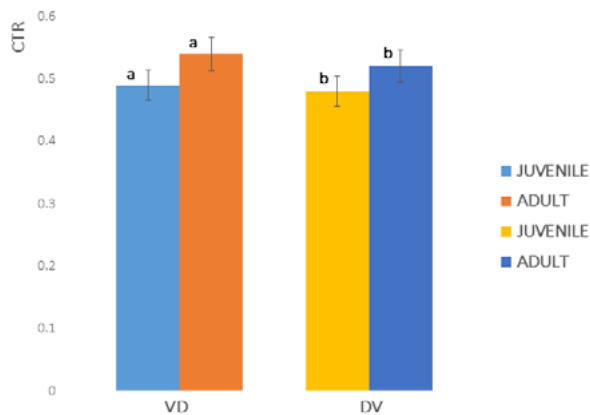
variable) and x being the nose-rump length. There was no significant linear correlation between the

radiographic values of CTR and nose-rump lengths in the adult ( $R^2: 0.46; P > 0.05$ ).

**Table 2** Cardiac diameter (CD), thoracic diameter (TD) and cardio-thoracic ratio (CTR) in juvenile and adult African grasscutter (*Thryonomys swinderianus*)

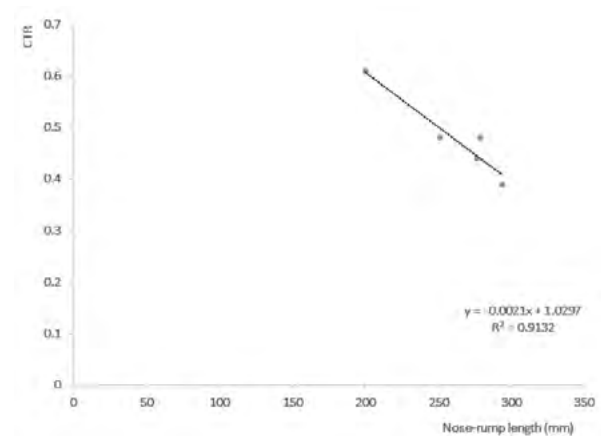
	JUVENILES		ADULTS	
	VD	DV	VD	DV
<b>Radiographic Indices</b>				
<b>CD (mm)</b>	21.64 ± 1.04 <sup>a</sup>	21.67 ± 1.59 <sup>a</sup>	35.23 ± 1.46 <sup>b</sup>	35.87 ± 52.09 <sup>b</sup>
<b>TD (mm)</b>	44.72 ± 3.96 <sup>c</sup>	47.25 ± 4.37 <sup>c</sup>	64.80 ± 43.31 <sup>d</sup>	68.78 ± 83.95 <sup>d</sup>
<b>CTR</b>	0.49 ± 0.04 <sup>e</sup>	0.48 ± 0.04 <sup>e</sup>	0.54 ± 0.01 <sup>f</sup>	0.52 ± 0.01 <sup>f</sup>

<sup>a-f</sup>Mean (± SEM) values of a radiographic thoracic index in an age group with the same alphabet superscript are not statistically different ( $P > 0.05$ )



**Figure 4** Comparison of mean values of CTR between juvenile and adult African grasscutters in the VD and DV radiographic views.

Mean values of CTR with the same letter superscript in each radiographic view are not statistically significant ( $P > 0.05$ )



**Figure 5** Negative linear relationship between CTR and nose-rump length in juvenile African grasscutter ( $P < 0.05$ )

**Comparison of VHS between juvenile and adult African grasscutters**

The mean radiographic values of the VHS obtained on the RtL and LeL projections in the juvenile were  $8.20 \pm 0.30$  and  $8.20 \pm 0.30$ , respectively. There was no significant difference in these values ( $P > 0.05$ ). Similarly, the mean radiographic

values of the VHS obtained on the RtL and LeL projections in the adults were  $9.00 \pm 0.16$  and  $9.20 \pm 0.12$ , respectively, with no significant difference ( $P > 0.05$ ). Furthermore, there was no significant difference in the radiographic values of VHS between the juvenile and adult age groups obtained in either of the opposite projections ( $P > 0.05$ ). Lastly, there was no significant correlation

between the VHS and nose-rump length in both the juvenile and adult age groups ( $P > 0.05$ ).

### Comparison of CAR between juvenile and adult African grasscutters

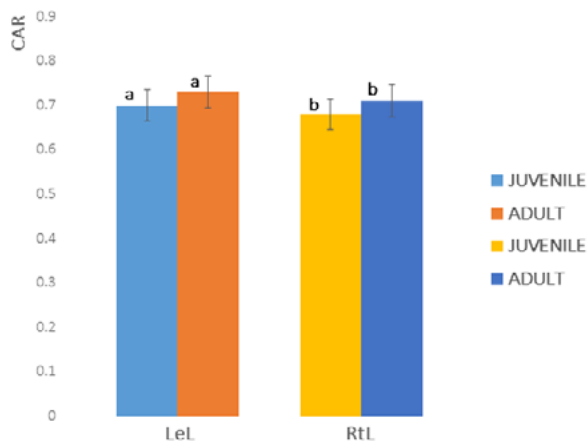
Table 3 shows the mean radiographic values of the SA, LA and CAR obtained on the RtL and LeL projections in each of the two age groups. There was no significant difference in the radiographic values of SA between the RtL and LeL projections in any of the two age groups ( $P > 0.05$ ). Similar findings were made for the LA and CAR. Figure 6 is a chart that compared the mean radiographic

values of CAR between juvenile and adult age groups, obtained on the RtL and LeL projections. The result did not show any statistical difference in mean radiographic values obtained on either the RtL or LeL projections ( $P > 0.05$ ). There was a significant negative linear correlation between the radiographic values of CAR and nose-rump length in the adults ( $R^2: 0.89$ ;  $P < 0.05$ ). A regression formula was deduced from the graph (Figure 7), as  $y = -0.0014x + 1.3536$ ;  $y$  being the CAR (dependent variable) and  $x$  being the nose-rump length. There was no significant linear correlation between the values of CAR and nose-rump lengths in the juvenile ( $R^2: 0.68$ ;  $P > 0.05$ ).

**Table 3** Short axis (SA), long axis (LA) and cardiac axis ratio (CAR) in the juvenile and adult African grasscutter (*Thryonomys swinderianus*)

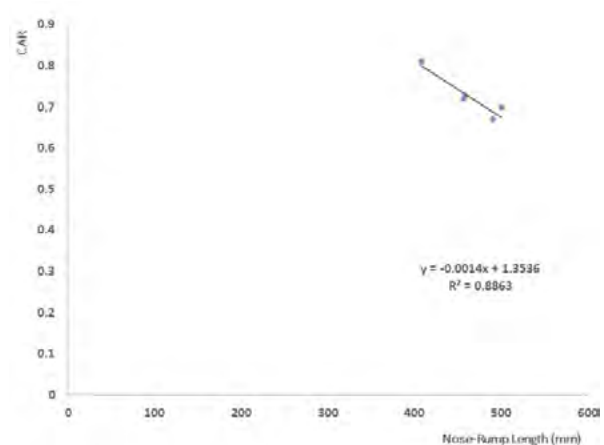
	JUVENILE		ADULT	
	LeL	RtL	LeL	RtL
<b>Radiographic Indices</b>				
<b>SA</b>	20.13 ± 1.18 <sup>a</sup>	20.68 ± 1.41 <sup>a</sup>	33.72 ± 2.4 <sup>b</sup>	33.54 ± 1.81 <sup>b</sup>
<b>LA</b>	29.31 ± 2.50 <sup>c</sup>	27.68 ± 2.68 <sup>c</sup>	46.53 ± 2.60 <sup>d</sup>	47.37 ± 2.60 <sup>d</sup>
<b>CAR</b>	0.70 ± 0.02 <sup>e</sup>	0.68 ± 0.01 <sup>e</sup>	0.73 ± 0.02 <sup>f</sup>	0.71 ± 0.01 <sup>f</sup>

<sup>a-f</sup>Mean (± SEM) values of a radiographic thoracic index in an age group with the same alphabet superscript are not statistically different ( $P > 0.05$ )



**Figure 6** Comparison of mean values of CAR of juvenile and adult African grasscutters in the LeL and RtL radiographic views.

Mean values of CAR with the same letter superscript in each radiographic view is not statistically significant ( $P > 0.05$ )



**Figure 7** Negative linear relationship between CAR and nose-rump length in adult African grasscutter ( $P < 0.05$ )



## DISCUSSION AND CONCLUSION

The establishment of radiographic reference values for the size of cardiac silhouette of any animal is a prerequisite for accurate radiographic diagnosis of cardiac disease in veterinary clinical practice. Studies have proved that the relationship between these radiographic values and variables such as age, breed and sex vary with animal species and even breeds of the same species. Unfortunately, the African grasscutter, a rodent of the *Thryonomyidae* family has only two recognized species (the second being *Thryonomys gregorianus*) and no classified breeds. To the best of our literature search, this is the first radiographic reference thoracic values available for this genus of rodents. Thus, this discussion is constrained to compare the findings with those of other rodents and mammals only. Furthermore, the sample size may be a limitation of the present study. However, a compilation of anatomical studies on the African grasscutter by Ibe et al. (2023) revealed that the rodent was nearly homogenous in morphotype. Moreover, the wide range of body weight in both juvenile and adult subjects in the present study infers that a higher sample size may not yield strikingly different values. It is also pertinent to emphasize that absolute caution was employed by the radiologist to ensure exposures were taken at full inspiration. This was to exclude bias due to change of cardiac axis with varied distention of the diaphragm.

The present study has reported a reference value of CTR in the African grasscutter, measuring an average of 0.52 on the VD and 0.50 on the DV projections. This is comparable to the values of 0.53 on VD, and 0.50 on DV projections of Nigerian indigenous dogs reported by Ukaha et al. (2021a). It is also comparable to the values of 0.51 and 0.52 obtained for male and female agouti, respectively, by De Moura et al. (2015) and values of 0.55 and 0.52 obtained for male and female tufted capuchin monkeys, respectively, by Rocha-Neto et al. (2015). It is, however, less than the value of 0.56 obtained for bats by Gardner et al. (2007). Dimopoulou et al. (2013) opined that CTR of more than 0.55 indicated cardiomegaly in

humans. Unfortunately, there is no reference value of CTR in African grasscutters with confirmed state of cardiomegaly or microcardia.

The values of CTR obtained on the VD and DV views of the African grasscutter from this study did not differ significantly, irrespective of age. Sak and Pazvant (2021) made similar observation in the Persian cats. There are divergent views as to the preferred radiographic projection for cardiac mensuration; Buchanan (2000) advocates the preferred use of DV projections in dogs because cardiac contours are more consistent and the heart is magnified in VD radiographs due to the varied distance between the heart and the radiographic cassette. Conversely, Van Den Broek and Darke (1987) preferred VD to DV views for determination of CTR in cats. The present study and that of Sak and Pazvant (2021) have shown that either view can be applied for the establishment of CTR in animals.

The significant negative correlation obtained between CTR and nose-rump length in the juvenile African grasscutter from this study implies that the value of CTR decreased with an increase in nose-rump length at approximately the same rate in the juvenile African grasscutters. The regression formula generated can be used to estimate CTR in juvenile African grasscutters of known nose-rump length. This is beneficial in clinical practice where there is no access to an X-ray machine for the radiographic evaluation of CTR.

This study has also presented reference values of VHS in juvenile and adult African grasscutters, without any significant difference between the two age groups. Similarly, Sleeper and Buchanan (2001) reported that the difference in VHS between young and adult dogs were not significant. Likewise, Black et al. (2011) observed that there was no significant difference in VHS between younger and older African hedgehogs. This implies that VHS does not depend on age of the animal, at least in the dogs, African hedgehogs and African grasscutter; thus, this clinical standard used in the determination of heart size in the adult African grasscutter can also be used in the juvenile.

The reference value of VHS for the African grasscutter from this study (8.7) is higher than the values of 7.5, 7.7, 8.1 or 8.2 established for adult cats, irrespective of breed (Litster and Buchanan, 2000), pet rats (Dias et al., 2021), agoutis (De Moura et al., 2015) and African hedgehogs (Black et al., 2011) respectively. It is lower than the values of 9.3, 9.4, 9.8, 10.1, 10.3 or 10.5 established for the tufted capuchin (Rocha-Neto et al., 2015), common marmosets (Wagner and Kirberger, 2005), Nigerian indigenous dog (Ukaha et al., 2021b), west African dwarf goats (Ukaha et al., 2013), dachshund dog (Birks et al., 2017) and Australian cattle dog (Luciani et al., 2019), respectively. This implies that the normal heart size in the adult African grasscutter is bigger than that of the rat and cat, but smaller than that of the above named non-human primates, small ruminant and breeds of dog. In the present study, there was no significant difference in the radiographic values of VHS between opposite projections in both the juvenile and adult African grasscutters. Ukaha et al. (2013), Ulum and Noviana (2018), Puccinelli et al. (2021) Sak and Pazvant (2021) and De Silva et al. (2022) made similar observation in the adult west African dwarf goats, laboratory mice, Chihuahua dog, Persian cats and guinea pigs, respectively. Conversely, Birks et al. (2017) and Luciani *et al.* (2021) observed that the VHS was significantly higher on the RtL than the LeL projections in the dachshund and Australian cattle dog breeds, respectively. These differences imply that significant breed and species variations exist in VHS of opposite radiographic projections. Thus, reference values of VHS must be intrinsic to the breed and/or species in view, and should not be extrapolated to other breeds or species. Furthermore, Dias et al. (2021) emphasized that VHS within normal limit of a named breed or species did not preclude an actual cardiac disease, mainly in cases where heart enlargement is not part of the process, as the animal can develop concentric cardiac hypertrophy without dilation. Further examination of the cardiac borders is advisable in such cases.

The values of CAR in the juvenile and adult African grasscutter from the present study did not differ significantly, neither was there any significant difference between the CAR of opposite projections in any of the two age groups. In their study, Ukaha et al. (2002) also observed that CAR between puppies and adult Nigerian indigenous dogs did not differ significantly. The authors also observed that CAR of opposite projections did not differ significantly in both the puppies and adult Nigerian indigenous dog. However, Ukaha et al. (2002) attributed the consistent (though, non-significant) higher value on the LeL projection to the higher value of LA on the RtL projection due to the pulling effect of the cardiophrenic ligament positioned on the left cardiac silhouette. This may also explain the reason CAR was also slightly higher on the LeL projection in the African grasscutter.

The significant negative correlation obtained between CAR and nose-rump length in the adult African grasscutter from this study implies that the value of CAR decreased with an increase in nose-rump length at approximately the same rate in the adult African grasscutters. The regression formula generated can be used to estimate CAR in adult African grasscutters of known nose-rump length. This is also beneficial in clinical practice where there is no access to an X-ray machine for the radiographic evaluation of CAR.

Reference values of CTR, VHS and CAR on radiographic projections of clinically healthy juvenile and adult African grasscutters have been provided in this study. These values will be beneficial to clinicians as objective tools to evaluate cardiac size in the juvenile and adult African grasscutters. They will also be beneficial for research purposes. There is a need for future studies to determine same values in African grasscutters with confirmed cases of microcardia or cardiomegaly.

## ACKNOWLEDGEMENTS

This research was sponsored by the Institution Based Research Grant of the Tertiary Education Trust Fund (TETFUND) of the Federal Republic of Nigeria (Research Grant No: TETF/DR&D/CE/UNIV/UMUDIKE/IBR/2020/VOL. 1)

## CONTRIBUTIONS

Concept - CSI, ROU; Design - CSI, ROU, NUN, KTJ, COU, YET, CJO, CU; Supervision - CSI; Resources - CSI, ROU; Materials - CSI; Data Collection and Processing - CSI, ROU, NUN,

KTJ, COU, YET, CJO, CU; Interpretation - CSI, ROU, NUN, KTJ, COU, YET, CJO, CU; Literature Search - CSI, ROU, NUN, KTJ, COU, YET, CJO, CU; Writing Manuscripts - CSI, ROU, NUN, KTJ, COU, YET, CJO, CU; Critical Review - CSI, ROU, NUN; All the authors approved the final manuscript.

## CONFLICT OF INTEREST

The authors declared that there is no conflict of interest.

## REFERENCES

- Baisan RA, Birsan O, Vulpei V. 2016. The diagnostic value of cardio-thoracic ratio in detecting heart size changes in dog. *Rev Rom Med Vet*, 26(3), 5-9.
- Birks R, Fine DM, Leach SB, Clay SE, Eason BD, Britt LG, et al. 2017. Breed-specific vertebral heart scale for the dachshund. *J Am Anim Hosp Assoc*, 53, 73-9. doi: <https://doi.org/10.5326/JAAHA-MS-6474>.
- Black PA, Marshall C, Seyfried AW, Bartin AM. 2011. Cardiac assessment of African hedgehogs, *Atelerix albiventris*. *J Zoo Wildl Med*, 42, 49-53. doi: <https://doi.org/10.1638/2010-0012.1>.
- Buchanan JW. 2000. Vertebral scale system to measure heart size in radiographs. *Vet Clin North Am Small Anim Pract*, 30(2), 379-93.
- De Moura CRC, Diniz AN, Moura LS, Sousa FCA, Baltazar PI, Freire LD, et al. 2015. Cardiothoracic ratio and vertebral heart scale in clinically normal black rumped agoutis (*Dasyprocta prymnolopha*, Wagler 1831). *J Zoo Wildl Med*, 46(2), 314-9.
- De Silva M, Bo P, Dora GE, Tagliavia C, Roccaro M, Grandis A, et al. 2022. Radiographic and anatomical morphometric assessments of heart size in presumed healthy pet guinea pigs. *Vet Radiol Ultrasound*, 63(1), 8-17. doi: <https://doi.org/10.1111/vru.13020>.
- Dennis R, Kirberger RM, Barr F, Wrigley RH. 2010. Other thoracic structures: pleural cavity, mediastinum, thoracic oesophagus, thoracic wall. In Dennis R, Kirberger RM, Barr F, Wrigley RH, et al (Eds), *Handbook of Small Animal Radiology and Ultrasound: Techniques and Differential Diagnoses* (2nd ed., pp. 199-226). London, UK: Churchill Livingstone Elsevier.
- Dias S, Anselmi C, Espada Y, Martorell J. 2021. Vertebral heart score to evaluate cardiac size in thoracic radiographs of 124 healthy rats (*Rattus norvegicus*). *Vet Radiol Ultrasound*, 62(4), 394-401. doi: <https://doi.org/10.1111/vru.12973>.
- Dimopoulos K, Giannakoulas G, Bendayan I, Liodakis E, Petraco R, Diller GP, et al. 2013. Cardiothoracic ratio from postero-anterior chest radiographs: A simple, reproducible and independent marker of disease severity and outcome in adults with congenital heart disease. *Int J Cardiol*, 166(2), 453-7. doi: <https://doi.org/10.1016/j.ijcard.2011.10.125>.
- Diniz AN, Silva JR, Ambrósio CE, Sousa JM, Sousa VR, Carvalho MAM, et al. 2013. Thoracic and heart biometrics of non-anesthetized agouti (*Dasyprocta prymnolopha* Wagler, 1831) measured on radiographic images. *Pesqui Vet Bras*, 33(3), 411-6.
- Gardner A, Thompson MSA, Fontenot D, Gibson N, Heard DJ. 2007. Radiographic evaluation of cardiac size in flying fox species (*Pteropus rodriguesi*, *P. hypomelanus*, and *P. vampyrus*). *J Zoo Wildl Med*, 38(2), 192-200. doi: [https://doi.org/10.1638/1042-7260\(2007\)038\[0192:REOCSI\]2.0.CO;2](https://doi.org/10.1638/1042-7260(2007)038[0192:REOCSI]2.0.CO;2)
- Gulanber EG, Gonenci R, Kaya U, Aksoy O, Biricik HAS. 2005. Vertebral scale system to measure heart size in thoracic radiographs of Turkish Shepherd (Kangal) dogs. *Turk J Vet Anim Sci*, 29, 723-6.
- Hansson K. 2004. Diagnostic Imaging of Cardiopulmonary Structures in Normal Dogs and Dogs with Mitral Regurgitation. Doctors. Dissertation. <http://www.diss-epsilon.slu-se/archives> (accessed 03.01.2020).
- Hemingway H, Shipley M, Christie D, Marmot M. 1998. Cardio-thoracic ratio and relative heart volume as predictors of coronary heart disease mortality. *Eur Heart J*, 19, 859-69. doi: <https://doi.org/10.1053/euhj.1997.0862>.
- Ibe CS, Ogbonnaya O, Ikpegbu E, Ani NV. 2023. Anatomical studies on the African grasscutter (*Thryonomys swinderianus*), a key component of the mini livestock industry in Nigeria. *Anat Rec*, 306(1), 226-34. doi: <https://doi.org/10.1002/ar.25049>.
- Litster AL, Buchanan JW. 2000. Vertebral scale system to measure heart size in radiographs of cats. *J Am Vet Med Assoc*, 216, 210-4. doi: <https://doi.org/10.2460/javma.2000.216.210>.

Luciani MG, Withoef JA, Pissetti MCH, de Souza PL, Sombrio SM, Bach EC, et al. 2019. Vertebral heart size in healthy Australian cattle dog. *Anat Histol Embryol*, 48, 264-7. doi: <https://doi.org/10.1111/ahe.12434>.

Oguntoyinbo AE, Adeoye PO, Ogunmodede JA, Bolarinwa AO, Ahmed HT, Adewara AA. 2016. Relationship between age, radiographic normal heart size and cardio-thoracic ratio in a Nigerian population. *East Afr Med J*, 93(2), 60-5.

Puccinelli C, Citi S, Vezzosi T, Garibaldi S, Tognetti R. 2021. A radiographic study of breed-specific vertebral heart score and vertebral left atrial size in Chihuahuas. *Vet Radiol Ultrasound*, 62(1), 20-6. doi: <https://doi.org/10.1111/vru.12919>.

Rahman MH, Aning GK, Addo P, Assare G, Hossain MI, Hossain MM, et al. 2015. Pathological investigation of the mortality in captive Grasscutter (*Thryonomys swinderianus*) colonies in Accra, Ghana. *Indian J Vet Pathol*, 39, 277-81. doi: <https://doi.org/10.5958/0973-970X.2015.00069.3>.

Rocha-Neto HJ, Moura LS, Pessoa GT, Ambrósio CE, Sousa FCA, Rodrigues RPS, et al. 2015. Cardiothoracic ratio and vertebral heart size (VHS) to standardize the heart size of the tufted capuchin (*Cebus apella* Linnaeus, 1758) in computerized radiographic images. *Pesqui Vet Bras*, 35(10), 853-8.

Sak D, Pazvant G. 2021. Estimation of vertebral heart size and cardiothoracic ratio in Persian cats. *Anat Histol Embryol*, 50(3), 543-9. doi: <https://doi.org/10.1111/ahe.12659>.

Sleeper MM, Buchanan JW. 2001. Vertebral scale system to measure heart size in growing puppies. *J Am Vet Med Assoc*,

219, 57-9. doi: <https://doi.org/10.2460/javma.2001.219.57>

Ukaha RO, Kene ROC, Agwu KK. 2002. Radiomorphometric studies of the thorax in Nigerian indigenous dog: Novel thoracic measurements. *Sokoto J Vet Sci*, 20(2), 75-86. doi: <http://dx.doi.org/10.4314/sokjvs.v20i2.1>.

Ukaha RO, Kene ROC, Agwu KK, 2021a. Cardiac size appraisals in thoracic radiographs of Nigerian Indigenous dogs: reference guides in clinical practice. *JoSVAS*, 1(1), 7-14.

Ukaha RO, Kene ROC, Agwu KK. 2021b. Vertebral heart size and cardiosternal contact evaluation in thoracic roentgenographs of the Nigerian indigenous dog. *JoSVAS*, 1(1), 67-72.

Ukaha RO, Kene ROC, Gbonko OE. 2013. Vertebral scale system to measure heart size in thoracic radiographs of West African dwarf goats. *Nig Vet J*, 34(4), 912-6.

Ulum MF, Noviana D. 2018. Radiographic measurement of cardiac size in laboratory mice. *ARSHI Vet Lett*, 2(1), 19-20. doi: <https://doi.org/10.29244/av1.2.1.19-20>.

VanDenBroekAHM, Darke PGG. 1987. Cardiac measurements on thoracic radiographs of cats. *J Small Anim Pract*, 28(2), 125-35. doi: <https://doi.org/10.1111/j.1748-5827.1987.tb05977.x>.

Wagner WM, Kirberger RM. 2005. Radiographic anatomy of the thorax and abdomen of the common marmoset (*Callithrix jacchus*). *Vet Radiol Ultrasound*, 46, 217-24. doi: <https://doi.org/10.1111/j.1740-8261.2005.00044.x>

## RADIOLOŠKI INDEKSI KARDIJALNIH MJERENJA KOD AFRIČKOGA DIVOVSKOG TRSTIČNOG ŠTAKORA (*THRYONOMYS SWINDERIANUS*)

### SAŽETAK

Cilj ovog istraživanja je odrediti referentne radiografske indekse za kardiorakalnu evaluaciju kod afričkoga divovskog trstičnog štakora. U istraživanje je uključeno dvadeset zdravih životinja istoga broja mladih i odraslih jedinki. Četrdeset torakalnih projekcija koje se sastoje od dorzoventralnih (DV), ventrodorzalnih (VD), desnih lateralnih (RtL) i lijevih lateralnih (LeL) snimaka je dobijeno. Evaluirani parametri su uključivali torakalne i kardijalne dijemetre na DV/VD snimcima te kardijalne duge i kratke osovine na RtL/LeL snimcima. Kardijalni indeksi koji su generirani uključivali su: kardio-torakalni omjer (CTR), vertebralni srčani skor (VHS) i omjer kardijalne osovine (CAR). Referentne vrijednosti za CTR na VD i DV su iznosile  $0.52 \pm 0.02$  i  $0.50 \pm 0.02$ . Razlika nije bila signifikantna ( $P > 0.05$ ). Srednje radiografske vrijednosti CTR-a za mlade i odrasle jedinke za DV su iznosile  $0.48 \pm 0.04$  i  $0.52 \pm 0.01$ . Referentne vrijednosti za VHS i RtL i LeL su iznosile  $8.70 \pm 0.23$  i  $8.60 \pm 0.21$ . Razlika nije bila signifikantna ( $P > 0.05$ ). Srednje vrijednosti za VHS za mlade i odrasle jedinke za RtL su iznosile  $8.20 \pm 0.30$  i  $9.20 \pm 0.12$ , Razlika nije bila signifikantna ( $P > 0.05$ ). Ovi indeksi su relevantni u budućem dijagnosticiranju kardijalnih oboljenja kod afričkoga divovskog trstičnog štakora u budućnosti.

**Ključne riječi:** Afrički divovski trstični štakor, kardio-torakalni omjer, omjer kardijalne osovine, radiologija, vertebralni srčani skor